

# FMRI Correlates of Pathologically Changes Alpha Rhythm in Patients with Hepatic Encephalopathy

Charité



11th Annual Meeting  
of the Organization for  
Human Brain Mapping  
June 12-16, 2005

Petra Ritter, Matthias Moosmann, Esmatollah Kasim, Arno Villringer

Berlin Neuroimaging Center, Depts. Neurology & Gastroenterology

Charité - Universitätsmedizin Berlin, Germany



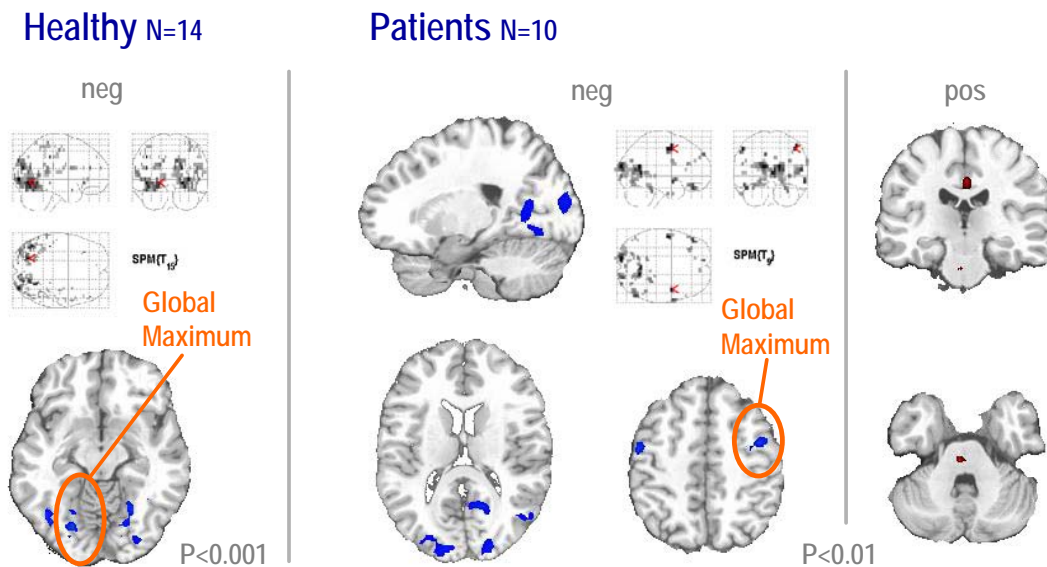
## Introduction

The simultaneous combination of EEG and fMRI has recently been shown to be capable of providing maps which are functionally related to the classical posterior alpha rhythm in healthy subjects (Goldman et al. 2002; Moosmann et al. 2003; Laufs et al. 2003). It has been reported (Kullmann et al. 2001) that patients with hepatic encephalopathy have altered topography of EEG background rhythms. Here we investigate fMRI correlates of pathologically changed alpha activity in ten patients (mean age 47 years, range 39-53) with hepatic encephalopathy.

However, alpha activity associated negative BOLD signal in the patients group was maximal in the frontal cortex bilaterally (figure), where no significant signal was found for healthy subjects. These results agree with electrophysiological findings of an anteriorized alpha rhythm in patients with hepatic encephalopathy (Kullmann et al. 2001).

## Conclusions

Simultaneous EEG-fMRI provides maps of areas which are involved in alpha rhythm generation. An occipital-to-frontal shift of alpha activity in patients with hepatic encephalopathy is associated with an occipital-to-frontal shift of maximal negative BOLD signal in fMRI.



## Methods

Patients were lying in the dark bore of a 1.5 T MR tomograph. EEG was recorded from 29 scalp positions (International 10-20 system, reference between Cz and Fz) using an MR-compatible EEG amplifier (Brain Products) and 32 channel EEG cap including one EOG and two ECG electrodes (Falk Minow Services). Patients were asked to stay awake and to be relaxed with eyes closed during the whole experiment. No other task was assigned. Functional MRI (BOLD sensitive gradient echo planar imaging sequence, TR=2 s, TA=1650 ms, 16 slices) and EEG (sampling frequency 5000 Hz) were acquired simultaneously. To obtain continuous EEG signal, artifacts related to MR-acquisition were corrected using an algorithm proposed by Allen et al. (Allen et al. 2000).

## Results

SPM group analysis (random effects N=10) yielded significant ( $p<0.01$ , uncorrected) alpha rhythm associated negative BOLD signal in the occipital cortex which is in concordance with former results by our and other groups (Goldman et al. 2002; Moosmann et al. 2003).

## References

- Allen PJ, Josephs O, Turner R (2000) A method for removing imaging artifact from continuous EEG recorded during functional MRI. *Neuroimage* 12: 230-239
- Goldman RI, Stern JM, Engel J, Jr., Cohen MS (2002) Simultaneous EEG and fMRI of the alpha rhythm. *Neuroreport* 13: 2487-2492
- Kullmann F, Hollerbach S, Lock G, Holstege A, Dierks T, Scholmerich J (2001) Brain electrical activity mapping of EEG for the diagnosis of (sub)clinical hepatic encephalopathy in chronic liver disease. *Eur J Gastroenterol Hepatol* 13: 513-522
- Laufs H, Kleinschmidt A, Beyerle A, Eger E, Salek-Haddadi A, Preibisch C, Krakow K (2003) EEG-correlated fMRI of human alpha activity. *Neuroimage* 19: 1463-1476
- Moosmann M, Ritter P, Krastel I, Brink A, Thees S, Blankenburg F, Taskin B, Obrig H, Villringer A (2003) Correlates of alpha rhythm in functional magnetic resonance imaging and near infrared spectroscopy. *Neuroimage* 20: 145-158

## Acknowledgements

This work was supported by the Federal Ministry for Education and Research BMBF (Berlin Neuroimaging Center).

## Contact

petra.ritter@charite.de